

Use of veno-venous extracorporeal membrane oxygenation and anesthetic implications during airway surgery in two toddlers

A. Weadock¹, V. Relli-Dempsey², J. D. Tobias³

¹Heritage College of Osteopathic Medicine – Dublin Campus, Dublin, Ohio and Ohio University, Athens, Ohio, USA

²Department of Anesthesiology, Doctor's Hospital, Columbus, Ohio, USA

³Department of Anesthesiology & Pain Medicine, Nationwide Children's Hospital and The Ohio State University College of Medicine, Columbus, Ohio, USA

Corresponding author: J. D. Tobias Department of Anesthesiology and Pain Medicine, Nationwide Children's Hospital and The Ohio State University College of Medicine, Columbus, Ohio, USA.

Email: Joseph.Tobias@Nationwidechildrens.org

Keypoints

1. First used clinically in 1972, extracorporeal membrane oxygenation (ECMO) is a form of cardiopulmonary bypass that has been used to support patients with cardiac or respiratory failure of various etiologies.
2. The process includes the drainage of blood from a large vein or the right atrium via a catheter into an oxygenator that removes carbon dioxide and supplies oxygen followed by return of the blood back into the circulation through a second catheter positioned on the arterial or venous side.
3. Technologic advancements with the manufacturing of single access, double lumen cannulas have optimized venous-venous ECMO for use in the perioperative setting, particularly in the pediatric population by eliminating the need for carotid access when respiratory support is needed during airway surgery.
4. VV ECMO use in the repair of tracheobronchial pathologies in pediatric patients is a safe and effective modality to facilitate surgical intervention by maintaining oxygenation and ventilation.
5. Use of the Avalon[®] dual-lumen catheter in pediatric patients using VV ECMO helps reduce the incidence of bleeding, infection, and neurologic complications associated with other means of cannulation and ECMO.

Abstract

Extracorporeal membrane oxygenation (ECMO) is a technology used with increasing frequency to support patients in cardiac or respiratory failure refractory to conventional therapies. As technologies have improved, the clinical indications for and applications of ECMO have been increased including its use in the peri-operative setting. Use of single access, double lumen cannulas have been instrumental in optimizing venous-venous (VV ECMO) for use in the perioperative setting, particularly in the pediatric population. We report the use of VV-ECMO with a dual lumen Avalon[®] catheter during airway surgery in two pediatric patients. The potential

applications of ECMO in the operating room are reviewed, options for anesthetic care discussed, and perioperative concerns reviewed.

Keywords

extracorporeal membrane oxygenation; venous-venous ECMO; airway surgery; pediatric anesthesia

Introduction

Extracorporeal membrane oxygenation (ECMO) is a technology used with increasing frequency to support patients in cardiac and/or respiratory failure that is refractory to conventional therapies. Use of extracorporeal life

support (ECLS) in the pediatric population has more than doubled over the last three decades with improvements in overall morbidity and mortality as technologies continue to advance.¹⁻⁴ The two modalities of ECMO, venous-arterial (VA ECMO) and venous-venous (VV ECMO), are selected based on the indication for initiation of ECMO, primarily whether cardiac support is needed. VA ECMO is used in the setting of cardiac failure, with or without respiratory failure; while VV ECMO is used in the setting of respiratory failure without cardiac dysfunction.^{5,6} Although initially reserved for urgent or emergent cardiac or respiratory support in the ICU, the use of ECMO in the perioperative setting for short-term cardiac and respiratory support during interventional surgeries and procedures has increased, remaining an important area for further investigation.⁷⁻¹²

Several of these anecdotal clinical reports have noted VV ECMO to be a safe and effective means of providing oxygenation and carbon dioxide removal in patients undergoing critical airway surgery.⁷⁻¹⁰ One important innovation enabling increased utilization of perioperative ECMO has been the development of single access, dual-lumen catheters, which were first developed in 1989.¹³⁻¹⁵ These dual lumen catheters enable the use of a single access site, typically the right internal jugular vein, decreasing the risks of infection, bleeding, and recirculation as seen in earlier cases of VV ECMO that utilized two single lumen cannulas.^{1,6,16} Additional advancements and refinements of the technology have included decreased size of the circuit, improvements in biocompatibility of the internal lumen of ECMO cannulas, and improvements in anticoagulation management. We report the use of VV ECMO with a dual lumen Avalon[®] catheter during airway surgery in two pediatric patients. The potential applications of ECMO in the operating room are reviewed, options for anesthetic care discussed, and perioperative concerns reviewed.

Case report

Review of these cases and presentation in this format followed the guidelines of the Institutional Review Board of Nationwide Children's Hospital (Columbus, Ohio). Informed consent was obtained from a parent for anesthetic care and use of deidentified patient data for publication purposes.

Patient #1: The patient was a 15-month-old, 15.4 kg boy who presented to the emergency department as a level 1 trauma following a motor vehicle accident in which he was an unrestrained passenger. Following the initial impact, he was noted by his mother to be gasping for air with perioral cyanosis, with Emergency Medical Services (EMS) personnel reporting an initial GCS 15. On arrival in the emergency department (ED), the patient was somnolent with a GCS of 4 and oxygen desaturation to 50% with tachypnea. Following the administration of ketamine (1 mg/kg) and rocuronium (1 mg/kg), his trachea was intubated with a 4.0 mm cuffed endotracheal tube on the first attempt. Subsequent imaging revealed bilateral pneumothoraces requiring placement of bilateral chest tubes. Computed tomography of the neck and chest was suggestive of tracheobronchial injury. He was transferred to the pediatric intensive care unit (PICU), with consults placed to pediatric otorhinolaryngology and cardiothoracic (CT) surgery. CT surgery advised surgical repair of tracheobronchial injury with exploratory thoracotomy. The decision was made to use VV ECMO to provide perioperative respiratory support and facilitate the repair. The proposed surgical procedure included repair of the airway injury with a tracheoplasty and on lay of an intercostal muscle flap. Prior to the OR, the patient was sedated with continuous infusions of fentanyl (2 µg/kg/hr) and dexmedetomidine (0.8 µg/kg/hr) with neuromuscular blockade provided by vecuronium (0.1 mg/kg/hr). After initial resuscitation and stabilization, the patient was transported to the operating room where routine American Society of Anesthesiologists' monitors were placed along with placement of a peripheral arterial

cannula and additional intravenous access. Intraoperatively, general anesthesia was initiated and maintained with intravenous infusions of fentanyl (2-3 $\mu\text{g}/\text{kg}/\text{hour}$), dexmedetomidine (0.8-1.8 $\mu\text{g}/\text{kg}/\text{hour}$), and inhaled isoflurane (expiratory concentration 0.4-0.5%), supplemented by bolus doses of fentanyl and midazolam. Following the induction of anesthesia, a bolus dose of 1250 units of heparin was administered in preparation for ECMO cannulation. A 19-French Avalon[®] catheter was placed in the right internal jugular vein using a modified Seldinger technique to a position 2 centimeters below the diaphragmatic margin (Figure 1). The Avalon[®] catheter was then connected to the ECMO circuit with ECMO flows and the inspired oxygen of the sweep gas adjusted to maintain adequate oxygenation and ventilation. Rigid bronchoscopy identified a large posterior tracheal wall tear extending from the thoracic inlet to the left main bronchus. This was repaired via thoracotomy with the use of an intercostal muscle flap. The patient was in the OR for a total of 5-6 hours. Intraoperative estimated blood loss was minimal and urine output was 35 mL. Postoperatively, VV-ECMO was continued and the patient was transported back to the PICU. A lung protective strategy with low ventilator settings was used during the first 72 postoperative hours to prevent barotrauma while VV ECMO was continued for respiratory support.

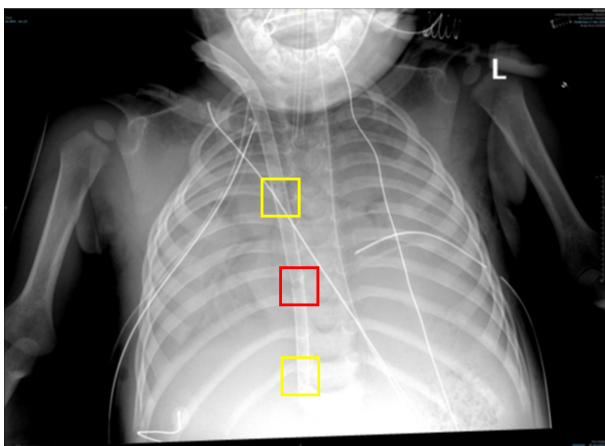


Figure 1. Postoperative chest radiograph showing the Avalon Elite bicaval dual lumen catheter positioned through the right internal jugular vein. The return port (red square) is positioned over the tricuspid valve while the two withdrawal ports are situated in the superior and inferior vena cavae (yellow squares).

On postoperative day 3, he was taken back to the OR for direct laryngoscopy and rigid bronchoscopy which revealed copious secretions. Antibiotic therapy was started with ampicillin-sulbactam and the cultures grew *M. cattarrhalis*. On postoperative day 4, there was a significant improvement in the clinical appearance of the chest radiograph. Given the improvement in his clinical status, ECMO support was weaned and discontinued on postoperative day 4 while mechanical ventilation was continued to provide full support of oxygenation and ventilation. During the ensuing days, aggressive chest physiotherapy and adjustments of his ventilator settings were required in the treatment of intermittent mucus plugging and atelectasis. On postoperative day 8, he was returned to the OR for a right video-assisted thoracotomy with decortication. On postoperative day 9, repeat direct laryngoscopy and rigid bronchoscopy were performed which revealed adequate healing of the surgical site. There was continued improvement in his respiratory status and his trachea was extubated to high-flow nasal cannula on postoperative day 10. Post-extubation stridor required treatment with racemic epinephrine and the administration of a helium-oxygen mixture. His respiratory status continued to improve and he was transferred to the inpatient ward on postoperative day 12 and then discharged home on hospital day 27. Following discharge, his clinical course has been stable. His last direct laryngoscopy and rigid bronchoscopy noted no evidence of scarring and that the trachea was well-healed. He has no long term cardiac, respiratory or neurologic sequelae.

Patient #2: A 2 year male patient weighing 12.4 kg presented to his primary care physician with two days of shortness of breath, cough, wheezing, stridor, fever, and vomiting. The patient was referred to our ED where a chest radiograph demonstrated a button battery (Figure 2). As part of consult from ENT and cardiothoracic surgery, an emergency direct laryngoscopy and bronchoscopy (DLB) and esophagoscopy was performed for removal of the foreign body (button battery). During

endoscopy, the patient was found to have a grade 3b erosive injury to the esophagus and posterior tracheal wall that was 6 mm in length and left vocal cord paralysis. Following the procedure, the patient's trachea remained intubated and he was admitted to the PICU. Sedation was continued with infusions of dexmedetomidine, fentanyl, and midazolam. Throughout the course of tracheal intubation and mechanical ventilation, vecuronium was administered for neuromuscular blockade.

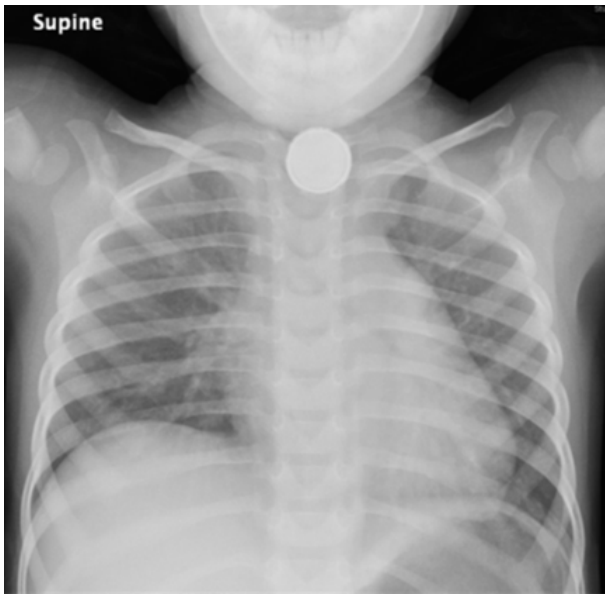


Figure 2. Chest radiograph of the second patient showing the button battery lodged in the upper esophagus.

On postoperative day 8, a repeat DLB revealed progression of the injury with right and left (traumatic) tracheoesophageal fistulas (TEF) formed. After surgical consultation, it was decided to use ECMO for perioperative respiratory support during repair of the TEF. Fourteen days after the initial ED admission, the patient was taken to the OR for median sternotomy and transthoracic repair of tracheal and esophageal injuries with an intercostal muscle flap. These procedures were performed using VV-ECMO for perioperative support. Following the induction of general anesthesia with inhaled sevoflurane and intravenous infusions of fentanyl, dexmedetomidine, and midazolam, heparinization was achieved. A 19-French Avalon® double lumen catheter was placed in the right internal jugular vein for VV-ECMO. Echocardiography was used to document correct placement and the

tip of the ECMO cannula which was positioned at the mid-right atrium at the end of placement. There was no interference with the IVC or tricuspid valve. The patient was then transferred to support of respiratory function with VV-ECMO circuit during intercostal muscle flap harvest and repair of the tracheal and esophageal injuries with a total ECMO time of 5 hours and 47 minutes. After the intercostal muscle flap tracheoplasty, bronchoscopy was repeated and revealed circumferential repair. Following repair, ECMO support was weaned and discontinued in the operating room. The patient was transferred to the PICU with ongoing endotracheal intubation and mechanical ventilation. His trachea was extubated with temporary support using BiPAP. Repeat DLB indicated that the repair site was intact, without a detectable leak. The postoperative course was complicated by difficulties with secretion clearance (difficulty breathing and stridor), requiring repeat tracheal intubation and mechanical ventilation. However, several days later, repeat DLB revealed dehiscence at the repair site. This required placement of a muscle flap to again repair the TEF on the right side, and a slide (intrathoracic) tracheoplasty. ECMO support was used again for this surgery. Cannulation occurred after the DLB and provided respiratory support to the patient during the sternotomy, tracheoplasty, transposition of the muscle flap, and repeat DLB. After the sternal incision was closed, the thoracic surgery team decannulated ECMO. A tracheostomy was placed for ongoing airway support and the patient transported to the ICU. Subsequently a DLB was performed and the tracheostomy tube was changed. At two week intervals over the next several weeks, the patient had repeat DLBs, tracheostomy tube changes, and evaluation of the surgical site. The patient was discharged home after 4-5 months in the hospital after the initial presentations. No pulmonary complications or sequelae were noted at follow-up visits. He has resumed some oral intake by mouth and has no long term residual neurologic deficits from his prolonged hospitalization.

Discussion

While discussions of the concept of cardiopulmonary bypass (CPB) date back to the early 1800s, the earliest clinical application of CPB was in 1951, using a device invented by Clarence Dennis during an atrial septal defect repair in a 15 month old child.^{17,18} Subsequent developments in the CPB machine including the membrane oxygenator, techniques of cannulation, pharmacology and monitoring of anticoagulation, and perioperative management led to the widespread applications of the technique and improvements in meaningful survival.¹⁸

Bartlett et al. reported the first use of VA-ECMO to treat respiratory failure in 13 neonates and infants with the long-term survival of 4 patients.³ Subsequent work by the same investigators reported the use of VA-ECMO in 16 moribund newborn infants.⁴ Survival was reported in 6 of these infants which the authors noted compared favorably to a mortality rate of 90% in a parallel series of 21 infants treated with conventional ventilator therapy. Improvements in technical and clinical aspects of ECMO led to further improvements in survival with subsequent expansion of its clinical applications to older patients and to support patients during either respiratory or cardiac failure.¹⁹

ECMO is generally applied in one of two distinct clinical scenarios, either to support respiratory or cardiac function. Although the initial applications of ECMO were in neonates to provide respiratory support in patients with severe respiratory failure, subsequent work has demonstrated the potential for VA-ECMO to also support patients with cardiac failure. During VV-ECMO, blood is circulated out of the body from the systemic circulation, is oxygenated and then returned to the systemic venous side, while VA-ECMO returns blood into the arterial system. VV-ECMO is used primarily for respiratory support while VA-ECMO, although used initially for respiratory support, can also provide support for a failing cardiovascular system related to various etiologies. One of the most recent and significant developments has been the introduction of a double lumen catheter which allows for

single cannulation through the IJ vein with both drainage and return of blood using the same catheter (Figure 1).¹⁴

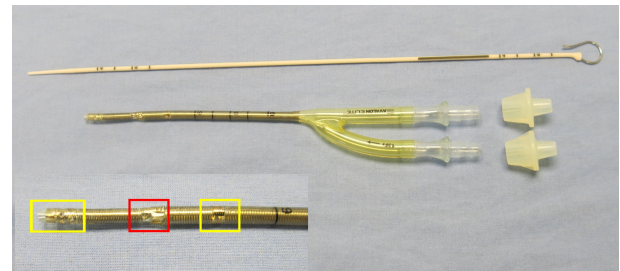


Figure 3. Photograph of the Avalon Elite bicaval dual lumen catheter (Getinge AB, Göteborg, Sweden) showing the two blood withdrawal ports (yellow squares) and return port (red square).

The bicaval catheter has been utilized in a variety of clinical situations, including temporary support of oxygenation and carbon dioxide removal during airway surgery as noted in our patient.

Despite its widespread use in the ICU setting, there remain only a handful of reports of the use of temporary ECMO intraoperatively to support respiratory or cardiac function during surgical procedures. Lebeskov et al. reported their experience with the use of VA ECMO via femoral vessel cannulation to support 27 high risk patients during transcatheter aortic valve replacement (TAVR).²⁰ There were no ECMO, hemodynamic or TAVR implantation complications. Decannulation of the ECMO system was performed in 92.6% of the patients at the end of the procedure in the hybrid-operating room suites. The mean duration of ECMO for procedure support was 51.4 minutes. Chakalov et al. reported the use of VV-ECMO to provide oxygenation and ventilation during surgical intervention for severe tracheal occlusion by a metastasis from advanced colon cancer in which an elective veno-venous extracorporeal membrane oxygenation (VV ECMO) was successfully used to provide a safe environment for surgery. Other authors have provided comprehensive reviews of the technique and considerations of ECMO support during airway surgery as well as references to other case reports and case series.^{22,23}

During intraoperative anesthetic care and the temporary use of ECMO support, modifications of care are needed

related to respiratory and cardiac function, anticoagulation, and the provision of anesthesia. In general, ECMO replaces mechanical ventilation and the role of the lungs in oxygenation and ventilation. Although in many cases, no respiratory support is needed, maintenance of mean airway pressure (MAP) is paramount to ensure that ECMO can be weaned and oxygenation and ventilation provided by the lungs during the immediate postoperative period when weaning from ECMO support. Mean airway pressure can be maintained by higher levels of PEEP and lower tidal volumes to avoid interference due to lung movement on the surgical field. During VV-ECMO, cardiovascular support may be needed, guided by usual intraoperative parameters with the administration of fluid and vasoactive medications directed at control of the determinants of cardiac output including preload, myocardial contractility, heart rate, and afterload.

As an artificial extracorporeal circuit is used during temporary ECMO support, some type of anticoagulation is generally indicated. The risk of bleeding and the development of pro-thrombotic state must be balanced when considering the approach to anticoagulation. Although unfractionated heparin remains the anticoagulant that is still primarily used given its ease of titration, the presence of a bedside point-of-care monitor (activated coagulation time), and reversibility of its effect with protamine. While there is a trend toward the use of direct thrombin inhibitors such as a bivalirudin as an anticoagulant during prolonged ECMO runs for respiratory failure, heparin remains the agent most commonly used intraoperatively for brief ECMO support.²³

The type and dose of anticoagulation used during intraoperative ECMO support should entail an individual assessment of the risk of bleeding vs thrombosis.²⁵ For patients undergoing airway procedures with short-term ECMO, bleeding is likely to pose a much greater risk than thrombotic complications of the patient or the circuit. In the adult population, various dosing strategies have been reported including administration of a single dose of heparin (3,000-5,000 units) at the time of cannulation to

prevent clot formation in the clamped, large-bore catheters. Once ECMO flows are established, thrombus formation in the circuit is less likely to occur. Alternatively, low dose heparin strategies for ECMO omit a bolus dose, but prime the circuit with 1,000 units. Given that no major circuit-related complications have been reported with the above strategies, low-dose heparin dosing for short-term ECMO procedural support (with or without protamine reversal) seems reasonable and may also obviate the need to monitor heparin effect as well as avoiding bleeding complications.

Additional concerns include potential damage to vasculature including perforation or thrombosis from placement of large bore cannula and the risk of dislodgement of cannula during intraoperative position change or patient transport.²⁶⁻²⁸ Minor changes in catheter positioning may also affect venous drainage or flows through the ECMO circuit. As minute ventilation may be limited or discontinued during ECMO support, the maintenance of anesthesia may need to be provided by a total intravenous anesthesia (TIVA) technique. The pharmacokinetics and volume of distribution of intravenously administered agents may be impacted by drug absorption to the oxygenator and the increased volume of distribution related to the ECMO circuit.

In summary, the intraoperative use of ECMO (both VA and VV techniques) may be used during specialized airway procedures as outlined in our patients. The novel Avalon[®] catheter allows VV-ECMO support through a single cannulation site, generally the IJ. During such care, specific modifications of intraoperative anesthetic care may be required related to cardiac and respiratory support. Additional aspects include anticoagulation management, alterations in the pharmacodynamics of anesthetic agents related to the ECMO circuit and oxygenator, as well as positioning concerns to ensure adequate catheter function. With these concerns in mind, VV ECMO can be used to support respiratory function during the repair of tracheobronchial pathologies in pediatric patients.

References

1. Valencia E, Nasr VG. Updates in pediatric extracorporeal membrane oxygenation. *J Cardiothorac Vasc Anesth.* 2020;34:1309-23.
2. Kelly B, Carton E. Extended indications for extracorporeal membrane oxygenation in the operating room. *J Intensive Care Med.* 2020;35:24-33.
3. Bartlett RH, Gazzaniga AB, Jefferies MR, Huxtable RF, Haiduc NJ, Fong SW. Extracorporeal membrane oxygenation (ECMO) cardiopulmonary support in infancy. *Trans Am Soc Artif Intern Organs.* 1976;22:80-93.
4. Bartlett RH, Gazzaniga AB, Huxtable RF, Schippers HC, O'Connor MJ, Jefferies MR. Extracorporeal circulation (ECMO) in neonatal respiratory failure. *J Thorac Cardiovasc Surg.* 1977;74(6):826-833.
5. Hill JD, O'Brien TG, Murray JJ, et al. Prolonged extracorporeal oxygenation for acute post-traumatic respiratory failure (shock-lung syndrome). *N Engl J Med.* 1972;286:629-634.
6. MacLaren G, Combes A, Bartlett RH. Contemporary extracorporeal membrane oxygenation for adult respiratory failure: life support in the new era. *Intensive Care Med.* 2012;38(2):210-220.
7. Hong Y, Jo KW, Lyu J, Huh JW, Hong SB, Jung SH, Kim JH, Choi CM. Use of venovenous extracorporeal membrane oxygenation in central airway obstruction to facilitate interventions leading to definitive airway security. *J Crit Care.* 2013;28(5):669-674.
8. Malpas G, Hung O, Gilchrist A, Wong C, Kent B, Hirsch GM, Hart RD. The use of extracorporeal membrane oxygenation in the anticipated difficult airway: a case report and systematic review. *Can J Anaesth.* 2018;65(6):685-697.
9. Schieren M, Böhmer A, Dusse F, Koryllos A, Wappler F, Defosse J. New approaches to airway management in tracheal resections - a systematic review and meta-analysis. *J Cardiothorac Vasc Anesth.* 2017;31(4):1351-1358.
10. Fung R, Stellios J, Bannon PG, Ananda A, Forrest P. Elective use of veno-venous extracorporeal membrane oxygenation and high-flow nasal oxygen for resection of subtotal malignant distal airway obstruction. *Anaesth Intensive Care.* 2017;45(1):88-91.
11. Kim MC, Ahn Y, Cho KH, Sim DS, Hong YJ, Kim JH, Jeong MH, Cho JG, Kim D, Lee K, Jeong I, Cho YS, Jung YH, Jeung KW. Benefit of extracorporeal membrane oxygenation before revascularization in patients with acute myocardial infarction complicated by profound cardiogenic shock after resuscitated cardiac arrest. *Korean Circ J.* 2021;51(6):533-544.
12. Chen L, Chen K, Ni H, Hong Y, Qian X, Pan K. Veno-arterial ECMO in the setting of post-infarct ventricular septal defect: a bridge to surgical repair. *Heart Lung Circ.* 2018;27(6):771-772.
13. Wang D, Zhou X, Liu X, Sidor B, Lynch J, Zwischenberger JB. Wang-Zwische double lumen cannula - Toward a percutaneous and ambulatory paracorporeal artificial lung. *ASAIO J.* 2008;54(6):606-611.
14. Javidfar J, Brodie D, Wang D, et al. Use of bicaval dual-lumen catheter for adult venovenous extracorporeal membrane oxygenation. *Ann Thorac Surg.* 2011;91(6):1763-1769.
15. Berdajs D. Bicaval dual-lumen cannula for venovenous extracorporeal membrane oxygenation: Avalon[®] cannula in childhood disease. *Perfusion.* 2015;30(3):182-186.
16. Lequier L, Horton SB, McMullan DM, Bartlett RH. Extracorporeal membrane oxygenation circuitry. *Pediatr Crit Care Med.* 2013;14(5 Suppl 1):S7-12.
17. Holman WL, Timpa J, Kirklin JK. Origins and evolution of extracorporeal circulation: JACC historical breakthroughs in perspective. *J Am Coll Cardiol.* 2022;79(16):1606-1622.
18. Stoney WS. Evolution of cardiopulmonary bypass. *Circulation.* 2009;119(21):2844-2853.
19. Bartlett RH. The story of ECMO. *Anesthesiology.* 2024;140(3):578-584.

20. Lesbekov T, Mussayev A, Alimbayev S, Kaliyev R, Kuanyshbek A, Faizov L, Nurmykhametova Z, Kunakbayeva A, Sadykova A. Prophylactic awake peripheral VA ECMO during TAVR. *J Clin Med.* 2023;12(3):859.
21. Chakalov I, Harnisch LO, Meyer AC, Moerer O. Preemptive veno-venous ECMO support in a patient with anticipated difficult airway: A case report. *Respir Med Case Rep.* 2020;30:101130.
22. Maxwell C, Forrest P. The role of ECMO support in airway procedures. *BJA Educ.* 2023;23:248-255.
23. Hoetzenecker K, Klepetko W, Keshavjee S, Cypel M. Extracorporeal support in airway surgery. *J Thorac Dis.* 2017;9:2108-2117.
24. M'Pembele R, Roth S, Metzger A, Nucaro A, Stroda A, Polzin A, Hollmann MW, Lurati Buse G, Huhn R. Evaluation of clinical outcomes in patients treated with heparin or direct thrombin inhibitors during extracorporeal membrane oxygenation: a systematic review and meta-analysis. *Thromb J.* 2022;20(1):42.
25. Chegondi M, Vijayakumar N, Totapally BR. Management of anticoagulation during extracorporeal membrane oxygenation in children. *Pediatr Rep.* 2022;14(3):320-332.
26. Jarboe MD, Gadepalli SK, Church JT, Arnold MA, Hirschl RB, Mychaliska GB. Avalon catheters in pediatric patients requiring ECMO: Placement and migration problems. *J Pediatr Surg.* 2018;53:159-162.
27. Haji JY, Mehra S, Doraiswamy P. Awake ECMO and mobilizing patients on ECMO. *Indian J Thorac Cardiovasc Surg.* 2021 Apr;37(Suppl 2):309-318.
28. Nakanaga H, Kinoshita T, Fujii H, Nagashima K, Tabata M. Temporary venovenous extracorporeal membrane oxygenation after cardiopulmonary bypass in minimally invasive cardiac surgery via right minithoracotomy. *JTCVS Tech.* 2023;20:99-104.